

Thoracic aortic aneurysm repair in three patients after heart transplantation: a case series

Jerzy Sadowski, Bogusław Kapelak, Karol Wierzbicki, Jacek Piatek, Krzysztof Wrobel, Janusz Konstanty-Kalandyć, Krzysztof Bartus, Piotr Wegrzyn, Mariola Labuz, Piotr Przybyłowski



Department of Cardiovascular Surgery and Transplantology, Institute of Cardiology Collegium Medicum, Jagiellonian University, John Paul II Hospital, Cracow, Poland

Kardiochirurgia i Torakochirurgia Polska 2009; 6 (2): 128–130

Abstract

Thoracic aortic aneurysm after heart transplantation is a rare but serious complication. The authors describe 3 cases (0.6%) of thoracic aortic aneurysm during 20 years of follow-up on 485 heart transplant patients at their institution. Dissected and non-dissected thoracic aortic aneurysms, diagnosed 23 to 38 months post transplantation, were treated with surgical repair or repeat transplantation. Two patients died postoperatively of multiorgan failure, including one with septic shock. One patient was discharged in good health. Surgical repair of aortic lesions in cardiac allograft patients, including repeat transplantation in cases of allograft vasculopathy, continue to carry substantial risk to the patient.

Key words: thoracic; aneurysm, aortic; transplantation, heart; surgery, complications.

Introduction

Diseases of donor and recipient aortas are rare but dangerous complications after heart transplantation [1]. In our department, 485 heart transplantation procedures including 2 repeat transplantations were performed between 1988 and 2007. This paper describes 3 cases (0.6%) of thoracic aortic aneurysm occurring during this 19-year follow-up period.

Patients

All patients provided verbal informed consent for inclusion of their cases in this publication. Approval was obtained from the appropriate ethics board and institutional review board for this research.

Patient 1

This 48-year-old man received a control coronary angiography because of transplant vasculopathy 38 months post heart transplantation. The angiographic examination revealed a chronic aortic aneurysm with dissection type II De Bakey. A 10-cm dissection that terminated in the aortic suture line was confirmed by computed tomography (CT) scan. Due to vasculopathy with left ventricular ejection fraction 20%,

retransplantation was performed. The donor aorta was successfully anastomosed with no resulting changes to the recipient aorta. After surgery, high doses of inotropic agents, mechanical ventilation, and broad-spectrum antibiotics were required. Due to anuria through the second postoperative day, the patient required haemodialysis. Despite intensive treatment, the patient's overall medical condition remained severe and multiorgan dysfunction ensued. The patient died 10 days after the repeat transplantation procedure.

Patient 2

A 53-year-old man was admitted 36 months post heart transplantation for recurrent severe pain between the shoulder blades, severe dyspnoea at rest, and syncope. The chest X-ray, echocardiography, and angio-CT scan of the thoracic aorta revealed a huge non-dissected aneurysm of the ascending aorta and aortic arch with maximum diameter 14.5 cm (Fig. 1). The aneurysm extended up to the origin of the left subclavian artery and caused constriction of the trachea. Emergency aneurysmectomy was pursued based on first symptoms of recurrent laryngeal nerve compression (cough) and severe dyspnoea at rest. During the operation, a pseudoaneurysm (maximum dimension

Adres do korespondencji: Piotr Wegrzyn, MD, Department of Cardiovascular Surgery and Transplantology, Institute of Cardiology Collegium Medicum, Jagiellonian University John Paul II Hospital, Piłsudskiego 80 Str., 31-202 Kraków, Poland, tel.: + 48 12 614 30 75, fax: +48 12 429 33 00, Email: peter-wegrzyn@o2.pl

12 cm) originating in the suture line was observed. The aneurysmectomy was performed using extracorporeal circulation (arterial cannulation through the femoral artery) in deep hypothermia with temporal cardiac arrest. Alloplasty of the aorta was performed using a 28-mm straight prosthesis (Sulzer Vascutek, Renfrewshire, UK) with hone-shaped anastomosis of extracranial arteries into the prosthesis. In the postoperative period, multiorgan dysfunction and septic shock (*Pseudomonas aeruginosa*) occurred. The patient died on the 20th day post surgery.

Patient 3

A 53-year-old man was admitted to the hospital with severe right ventricular failure 23 months post heart transplantation. Based on echocardiography and aortography, an aneurysm of the Valsalva sinus was diagnosed. Due to difficulty interpreting these imaging tests, magnetic resonance imaging (MRI) and CT scan were performed, which identified a pseudoaneurysm originating in the ascending aorta suture line causing compression of the pulmonary artery and right ventricle (Fig. 2). The aneurysmectomy was done by use of extracorporeal circulation (femoral artery cannulation) in deep hypothermia with temporal cardiac arrest. After removal of the pseudoaneurysm, lateral plasty of the ascending aorta was performed using a Hemashield Gold patch (Boston Scientific Corporation, Natick, Massachusetts). Intraoperatively, *Pseudomonas*-like signs of infection were present (*Pseudomonas aeruginosa*) and antibiotics (imipenem-cilastatin, amoxicillin clavulanate, and metronidazole) were administered. The patient was discharged in good condition after 50 days of hospitalization.

Comment

Heart transplantation remains the most effective treatment for end-stage heart failure. The introduction of new, individually adapted immunosuppressive therapy models, as well as improvements in postoperative care, have improved the life expectancy and quality of life after heart transplantation [2]. The most frequent factors limiting life expectancy in the first year after heart transplantation are allograft failure, non-cytomegalovirus infection, multi-organ failure, and acute rejection [3]. In the long term (i.e. > 5 years), the most important contributors to mortality are allograft vasculopathy, late graft failure, malignant tumours, and non-cytomegalovirus infection [3].

Although relatively rare, aortic lesions post heart transplantation are considered to be an adverse consequence of the transplantation itself and the required immunosuppressive therapy [5]. Denervation of the transplanted heart and the absence of early chest pain make timely diagnosis particularly challenging [4]. Aortic lesions tend to progress such that surgical repair or repeat transplantation is necessary [5].

Reports of aortic aneurysm in cardiac allograft patients in the literature are sparse. Vigano reported on a series of 9 cardiac allograft patients with aortic complications, including dissected aneurysm, pseudoaneurysm, and aortic rupture [5]. It was noted that the most frequent risk factors for aortic aneurysm were infections, hypertension after heart transplantation, and compliance mismatch between the donor and recipient aorta. Hypertension (patients 1 and 2) and infection (patient 3) were present in our cases as well.

After heart transplantation, patients are at increased risk for serious infections as a result of the need for

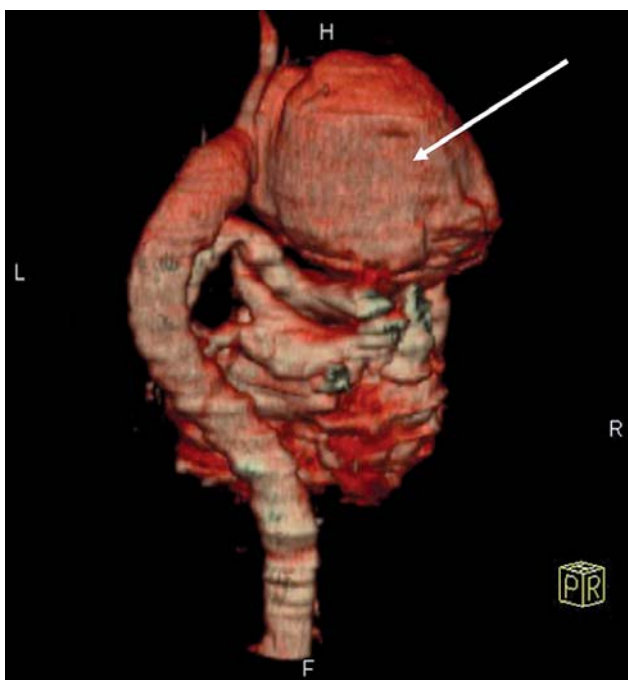


Fig. 1. Giant aneurysm of the ascending aorta and aortic arch (CT reconstruction) in patient 2

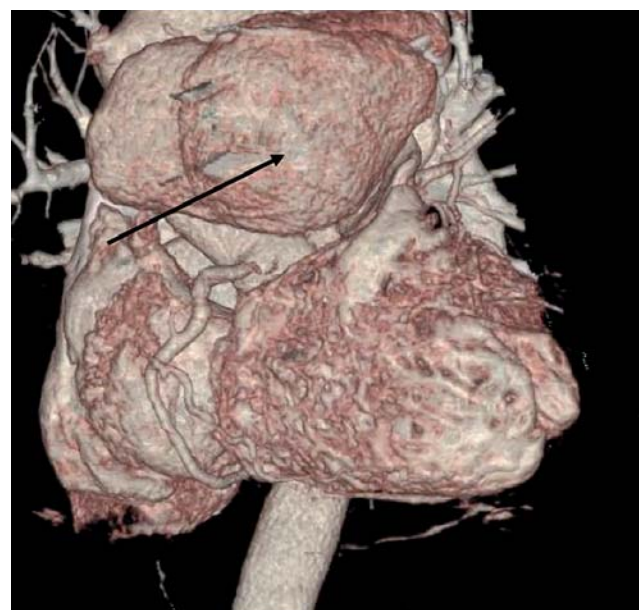

Fig. 2. Pseudoaneurysm originating in ascending aorta (suture line) with compression of pulmonary artery and right ventricle in patient 3

permanent immunosuppressive treatment to prevent graft rejection. The aggressive immunosuppression employed after repeat transplantation generates an additional risk of multiorgan dysfunction or general infection. Such complications appear to be major factors in determining post-operative results. Surgical repair of aortic lesions in cardiac allograft patients are often necessary, with repeat transplantation being the “procedure of choice” in cases of graft vasculopathy, though such surgeries continue to carry substantial risk to the patient.

Acknowledgments

The authors thank Laurie LaRusso, MS, ELS, for editorial assistance in preparing this manuscript with funding from ATS Medical, Inc.

References

1. Schellemans C, Tack W, Vanderheyden M. Acute type A aortic dissection in a cardiac allograft recipient: case report and review of the literature. *Heart* 2004; 90: 1256-1258.
2. Przybyłowski P, Wierzbicki K, Sadowski J, Kapelak B. *Heart Transplant Terapia* 2003; 3: 134.
3. Taylor DO, Edwards LB, Aurora P, Christie JD, Dobbels F, Kirk R, Rahmel AO, Kucheryavaya AY, Hertz ML. Registry of the International Society for Heart and Lung Transplantation: Twenty-fifth Official Adult Heart Transplant Report – 2008. *J Heart Lung Transplant* 2008; 27: 943-956.
4. Kirklin JK, Young JB, McGiffin DC. *Heart transplantation*. Churchill Livingstone; 2002: 16
5. Vigano' M, Rinaldi M, D'Armini AM, Pederzoli C, Minzioni G, Grande AM. The spectrum of aortic complications after heart transplantation. *Ann Thorac Surg* 1999; 68: 105-111.
6. Klotz S, Hammel D, Schmidt C, Scheld HH. False aneurysm of ascending aorta anastomosis after orthotopic heart transplantation. *Eur J Cardiothorac Surg* 2001; 20: 847.